

MULTIPLE CONGENITAL MALFORMATIONS OF A NELLORE CALF CASE REPORT

DEFEITOS CONGÊNITOS MÚLTIPLOS EM BEZERRO NELORE RELATO DE CASO

R. YANAKA^{1*}, H. N. FERREIRA², M. M. Q. ASSIS³, G. K. OLIVEIRA³, V. B. ALBUQUERQUE³, V. C. SARTORI³

SUMMARY

Congenital malformations have become more frequent in large animal clinics. Anal atresia is a congenital malformation that has been previously reported in several species and it is normally associated with other malformations, such as urethrorectal fistula, pseudohermaphroditism, rectovaginal fistula, accessory scrotum, diphallia, renal agenesis, renal and ureteral fusion and skeletal malformations as well. This case report describes the multiple congenital malformations of a Nelore calf. Some of the malformations observed in this case were different from those reported in the literature, especially the failure in the formation of ventral midline structures of the animal. Radiographic examination was of great importance for the diagnosis and especially to assess the involvement of other structures. Due to multiple malformations and the poor prognosis, the calf was euthanized and it was concluded that cases of anal atresia must be further investigated for associated problems that could risk life or productivity of the animal.

KEY-WORDS: Agenesis. Anal atresia. Bovine. Patent urachus. Renal hypoplasia.

RESUMO

Os defeitos congênitos têm se tornado mais frequentes na rotina clínica de grandes animais. A atresia anal é um defeito congênito já relatado em diversas espécies, e normalmente associado a outras malformações, como fistula uretrorretal e pseudo-hermafroditismo, fistula retovaginal, bolsa escrotal acessória, difalia, agenesia renal, fusão renal e ureteral e malformações esqueléticas. Objetivou-se relatar o caso de um bezerro da raça Nelore apresentando múltiplos defeitos congênitos. Algumas alterações observadas no presente caso diferiram das citadas na literatura, sendo a principal a falha na formação de estruturas na linha média ventral do animal. O exame radiográfico foi de grande importância para a confirmação do diagnóstico, e principalmente para a avaliação do comprometimento de outras estruturas. Devido à presença de múltiplas malformações, o prognóstico era desfavorável quanto à vida e função do animal, sendo indicada a eutanásia, razão pela qual se conclui que os casos de atresia anal devem ser investigados mais profundamente, na busca por defeitos concomitantes que possam inviabilizar a vida e/ou produtividade do animal.

PALAVRAS-CHAVE: Agenesia. Atresia anal. Bovino. Hipoplasia renal. Úraco persistente.

¹ Universidade Federal Rural de Pernambuco, Unidade Acadêmica de Garanhuns. Av. Bom Pastor, s/n, Boa Vista, ZIP Code 55292-270, Garanhuns-PE, Brazil. Correspondence author: rodrigo_yanaka@uag.ufpe.br.

² Faculdade Pio Décimo, Aracajú-SE, Brazil.

³ Faculdade Integrado de Campo Mourão, Unidade Campus, Campo Mourão-PR, Brazil.

INTRODUCTION

Birth defects have become more frequent in the clinical routine of large animals, primarily beef cattle that resulted from biotechnologies, such as embryo transfer (ET), in vitro fertilization (IVF) and cloning, usually these animals have thicker umbilical stump, predisposing them to omphalitis and persistent urachus, as suggested by Batchelder et al. (2007). Besides the influence of cell manipulation inherent to the several biotechnical processes used in cattle, other factors are related to the occurrence of birth defects during fetal development such as, genetic abnormalities, environmental insult by chemical and physical agents, hereditary chromosomal abnormalities, infectious diseases, nutritional deficiencies, poisoning plants and teratogenic effects of environmental changes caused by humans (RADOSTITS et al., 2007).

Anal atresia is a congenital malformation reported in pigs, sheep as well as beef and dairy calves (RADOSTITS et al., 2007). It has been reported less frequently in dairy cattle, and may be associated with the absence of tail, presence of a fistula between the rectum and the reproductive tract, and urinary tract abnormalities (STEINER, 2004). The concomitant atresia of the rectum is considered a rare condition in calves (WEAVER et al., 2005).

A survey conducted by Campos et al. (2009) in the state of Pará diagnosed 27 cases of congenital malformations in 39 calves assessed during the period between 1999 and 2009, but only one case of anal atresia associated with recto-vaginal fistula was observed. On the other hand, Kiliç & Sarierler (2004) reported during the period between 1999 and 2003, the occurrence of 61 cases of intestinal atresia in calves, and from these, 39 were referred for correction of anal atresia, while 5 had multiple abnormalities.

In the literature there are several reports of anal atresia, but with large variations of the associated defects. It has been reported that the absence of anal opening may be accompanied by genito-urinary changes, such as, urethrorectal fistula and pseudohermaphroditism (ROCHA et al., 2010), rectovaginal fistula (BADEM KIRAN et al., 2009), accessory scrotum (ROCHA et al., 2010; LOYNACHAN et al., 2006), diphallia (LOYNACHAN et al., 2006), renal agenesis (NOH et al., 2003, PEIRÓ et al., 2006), renal and ureteral fusion (JEONG et al., 2003) and skeletal malformations (NOH et al., 2003).

The diagnosis is usually given for 2 to 3 day-old animals, due to absence of defecation and increased volume of the perineal region, which may indicate rectal atresia (WEAVER et al., 2005). After 24 hours of birth, the affected animals present abdominal distension, colic, tenesmus and weakness (FUBINI & DIVERS, 2008).

This report describes the congenital malformations of a Nellore calf.

A Nellore calf aged three days old, was referred to the veterinary hospital with a history of normal delivery and gestation, with tenesmus and absence of anal opening. The calf, however, was eating normally and was not treated at the farm. The calf was produced by artificial insemination of a primiparous cow that had been used previously as embryo donor only, and other animals, from the same breeding, had no birth malformations.

On physical examination, there were no changes of the vital parameters, however, the animal was depressed. Upon inspection, it was observed that urine was being eliminated by the umbilical cord, which was enlarged (Figure 1A), as well as the presence of urethral fistula in the perineal region (Figure 1B), and the absence of the anal orifice (Figure 1B). On palpation, the umbilical stump was thickened and firm. It was also observed the absence of the penis and failure of skin closure in the midline, which extended from the perineal to the abdominal region (Figure 1B); non-union of the scrotum in the median raphe, in the presence of two testes; the presence of firm pedicle skin in the perineal region, and complete hard palate upon inspection of the oral cavity, but with apparent fusion failure of the hemi-mandibles (Figure 1C).

The plain radiographs of the abdomen showed a large amount of gas in the bowel and increased radiopacity near the pelvic region suggesting accumulation of feces in the rectum (Figure 1D), thus ruling out the possibility of concomitant rectal atresia, which was considered a rare condition in calves by Weaver et al. (2005). Contrast radiography through the urethra allowed the visualization of the bladder contour and the path from the urachus to the umbilical stump that confirmed the suspicion of persistent urachus.

Due to the various malformations observed, we opted to euthanize the animal, followed by necropsy to confirm the macroscopic changes mentioned above, during which, other malformations were observed: rectum distended by fecal content and adhered to the wall, but without opening (Figure 1E); adhesion in several intestinal segments; presence of a third hypoplastic kidney; as well as failure in the pelvic bone formation, also viewed radiographically (Figure 1F). The calf did not have female reproductive organs.

The correction of the anal atresia and persistent urachus would be possible as described by Weaver et al. (2005); however, as it has already been reported in the literature, this malformation is commonly accompanied by other congenital malformations. Therefore, a more detailed assessment is recommended to detect multiple malformations, as observed in the necropsy and previously described (PEIRÓ et al., 2006; KILIÇ & SARIERLER, 2004; BADEM KIRAN et al., 2009; ROCHA et al., 2010; LOYNACHAN et al., 2006; JEONG et al., 2003), since they may indicated poor prognosis for life or function of the animal. And, since it is not yet known if anal and/or intestinal atresia is hereditary or not, it is suggested that surgical repair is contraindicated for animal with reproductive function (KILIÇ & SARIERLER, 2004;

CASE REPORT

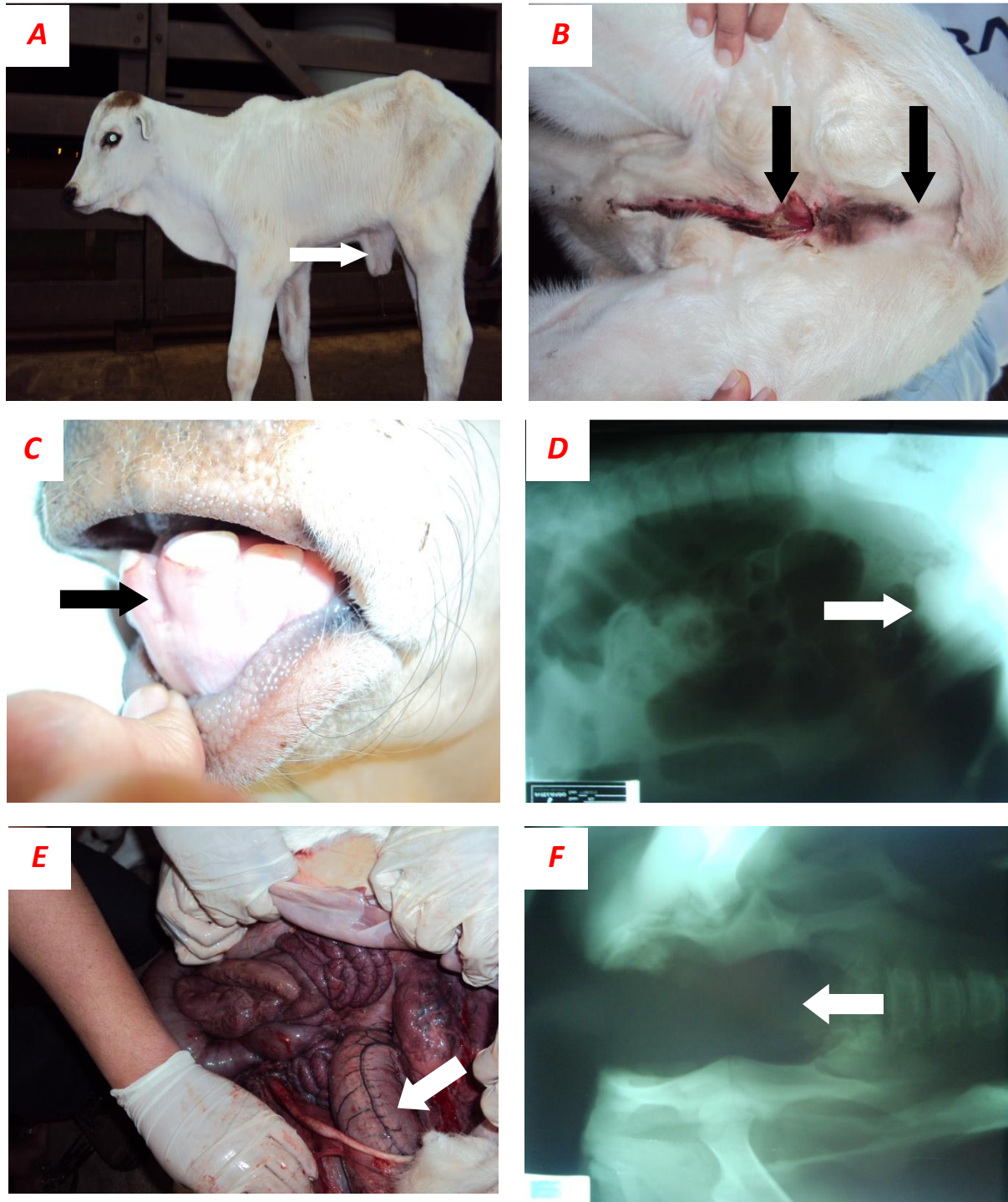


Figure 1 - The Nellore calf that presented persistent urachus and multiple congenital malformations. The arrow in *A* shows the increased umbilical volume. *B*, atresia anal (arrows) and failure of the midline skin closure from the perineal to the abdominal region, showing the urethra opening (arrow). *C*, mandible malformation (arrow). *D*, large amount of gas in the bowel and radiopacity that shows feces accumulation in the rectum (arrow). *E*, shows the final portion of the distended colon and rectum (arrow). *F*, malformation of the pelvis (arrow).

PEIRÓ et al., 2006; FUBINI & DIVERS, 2008), as the animal of this case.

According to Kiliç & Sarierler (2004), from the 39 calves with anal atresia, five were euthanized due to multiple malformations and 34 were treated surgically; and from these, 30 animals survived and developed normally, thus showing that when anal atresia is the only malformation, the prognosis is favorable, unlike those who present several concomitant malformations.

It was observed the importance of contrast and simple radiography for the diagnosis and to determine the degree of involvement of other structures, and since the bowel fills up with gas, it is easier to determined the extension of the malformation (PEIRÓ et al., 2006). Moreover, the radiological contrast allowed to confirm persistent urachus.

It was concluded that anal atresia, despite being easily diagnosed, should be investigated further to search for the presence of concomitant malformations that can impair life and/or productivity of the animal either early or late, thus making for poor prognosis in these cases.

REFERENCES

BADEMKIRAN, S.; İÇEN, H.; KURT, D. Congenital recto vaginal fistula with atresia ani in a heifer: a case report. *Y.Y.U. Veteriner Fakültesi Dergisi*, v.20, n.1, p.61-64, 2009.

BATCHELDER, C. A.; BERTOLINI, M.; MASON, J. B.; MOYER, A. L.; HOFFERT, K. A.; PETKOV, S. G.; FAMULA, T. R.; ANGELOS, J.; GEORGE, L. W.; ANDERSON, G. B. Perinatal physiology in cloned and normal calves: physical and clinical characteristics. *Cloning and Stem Cells*, v.9, n.1, p.63-82, 2007.

CAMPOS, K. F.; SOUSA, M. G. S.; SILVA, N. S.; OLIVEIRA, C. H. S.; DUARTE, M. D.; BARBOSA, J. D.; OLIVEIRA, C. M. C. Doenças congênitas em bovinos diagnosticadas pela central de diagnóstico veterinário (CEDIVET) da Universidade Federal do Pará, no período de 1999 a 2009. *Ciência Animal Brasileira*, supl.1, p.13-18, 2009.

FUBINI, S.; DIVERS, T. J. Noninfectious diseases of the gastrointestinal tract. In: DIVERS, T. J.; PEEK, S. F. *Rebhun's diseases of dairy cattle*. 2. Ed. St. Louis: Saunders Elsevier, 2008, p.130-199.

JEONG, W. I.; LEE, C. S.; RYU, S. Y.; WILLIAMS, B. H.; JEE, Y. H.; JUNG, C. Y.; PARK, S. J.; JEONG, D. H.; LEE, S. K.; JEONG, K. S. Renal and ureteral fusion in a calf with atresia ani. *Journal of Veterinary Medical Science*, v.65, n.3, p.413-414, 2003.

KILIÇ, N.; SARIERLER, M. Congenital intestinal atresia in calves: 61 cases (1999-2003). *Revue de Médecine Vétérinaire*, v.155, n.7, p.381-384, 2004.

LOYNACHAN, A. T.; JACKSON, C. B.; HARRISON, L. R. Complete diphallia, imperforate ani (type 2 atresia ani), and an accessory scrotum in a 5-day-old calf. *Journal of Veterinary Diagnostic Investigation*, v.18, p.408-412, 2006.

NOH, D. H.; JEONG, W. I.; LEE, C. S.; JUNG, C. Y.; CHUNG, J. Y.; JEE, Y. H.; DO, S. H.; AN, M. Y.; KWON, O. D.; WILLIAMS, B. H.; JEONG, K. S. Multiple congenital malformation in a Holstein Calf. *Journal of Comparative Pathology*, v.129, p.313-315, 2003.

PEIRÓ, J. R.; CARRENHO, L. C.; LOMBARDI, A. L.; SOARES, G. T.; CIARLINI, D. R.; SILVA, A. R. S.; YANAKA, R. Atresia anal e retal em bezerro – relato de caso. *Anais... VI Semana de Divulgação Científica do Curso de Medicina Veterinária – Unesp Araçatuba*, 2006.

RADOSTITS O. M.; GAY C. C.; HINCHCLIFF K. W.; CONSTABLE P. D. Diseases of the newborn. In: _____. *Veterinary medicine: a textbook of the diseases of cattle, horses, sheep, pigs and goats*. 10. ed. Philadelphia: Elsevier Saunders, 2007, 2156p.

ROCHA, T. G.; LASKOSKI, L. M.; LOPES, M. C. S.; BERLINGIERI, M. A.; MAGALHÃES, G. M.; ALESSI, A. C. Atresia anal, fistula uretroretal congênita, bolsa escrotal acessória e pseudo-hermafroditismo em bezerro mestiço. *Ciência Rural*, v.40, n.5, p.1231-1234, 2010.

STEINER, A. Surgery of the colon. In: FUBINI, S.; DUCHARME, N. *Farm animal surgery*. 1. Ed. St. Louis: Elsevier Saunders, 2004, p.472-477.

WEAVER, A. D.; JEAN, G. S.; STEINER, A. Abdominal surgery. In: _____. *Bovine surgery and lameness*. 2. Ed. Oxford: Blackwell Publishing, 2005, p.75-139.